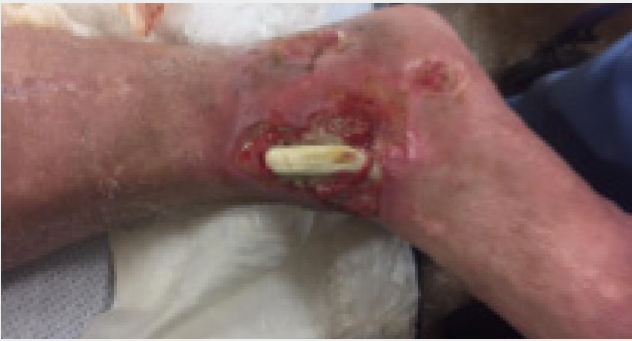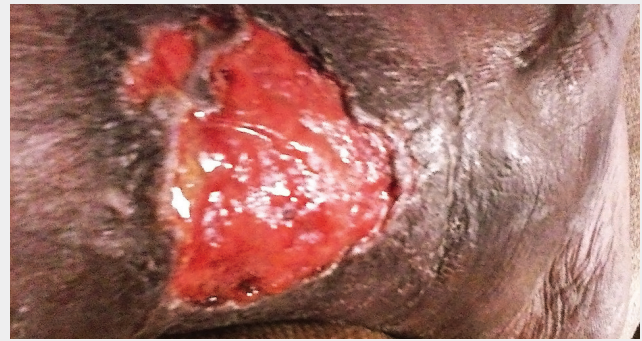


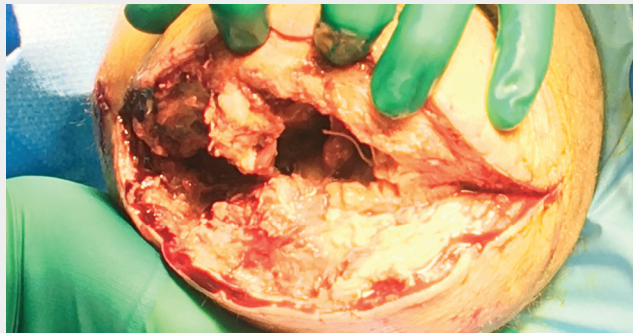
ADVANCED PLACENTAL-BASED ALLOGRAFTS SURGICAL LOWER EXTREMITY CASEBOOK



NOVEL APPROACH TO LIMB SALVAGE UTILIZING COVERAGE OF EXPOSED TENDON WITH AMNIOCORD® AND NEGATIVE PRESSURE WOUND THERAPY (NPWT)



3-YEAR CHRONIC VENOUS STASIS ULCER WITH DHACM AND NPWT



BELOW THE KNEE AMPUTATION (BKA) TO ABOVE THE KNEE AMPUTATION (AKA) AFTER RECURRENT DEHISCENCE

Novel Approach to Limb Salvage Utilizing Coverage of Exposed Tendon With AMNIOCORD and NPWT

David Kyle, DPM | Podiatric Surgeon | Huntsville, AL

Clinical History

A male patient with prior medical history of alcoholic neuropathy and severe Peripheral Arterial Disease (PAD) presented to the Emergency Department with a 10 cm x 6.5 cm wound with an exposed and desiccated tibialis anterior tendon (Figure 1). The patient had failed conservative care by a home care provider. The severity of the wound required immediate attention to salvage the limb.

Surgical Intervention

The patient was taken to the OR for debridement of the necrotic tissue and tibialis anterior tendon (Figure 2). In doing so, multiple structures were left exposed and required coverage that included the neurovascular bundle, anterior tibial artery, and dorsiflexory tendons. Two AMNIOCORD allografts were fenestrated (Figures 3 and 4) with a 15 blade on the back table in order to allow for expansion and greater area coverage. AMNIOCORD is a dehydrated human umbilical cord allograft that provides a protective environment to support the healing process. It protects the wound bed to aid in the development of granulation tissue. The product provides a human biocompatible extracellular matrix of hyaluronic acid and collagen and contains 250+ regulatory proteins.^{1,2} The AMNIOCORD grafts were secured in place with staples and dressed with NPWT.



Figure 4: AMNIOCORD

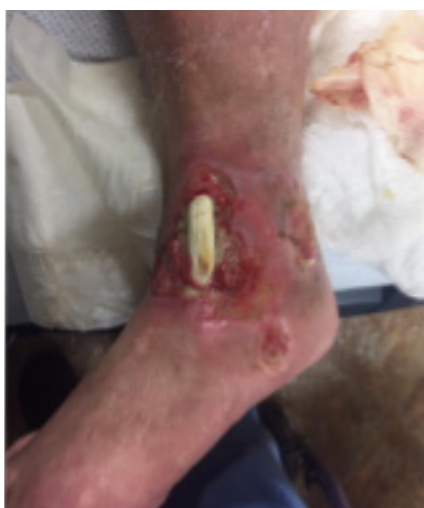

Figure 1: Day 0 presentation with exposed and desiccated Tibialis Anterior (TA) tendon

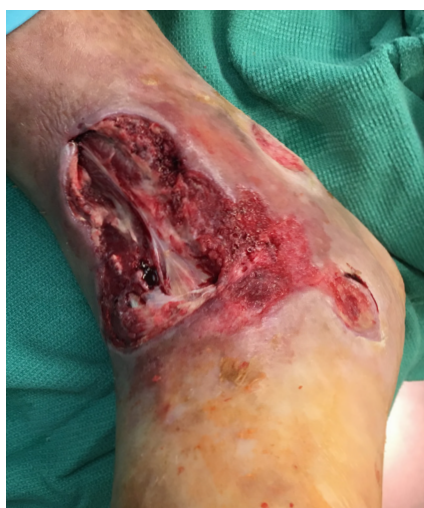

Figure 2: Day 0 debridement

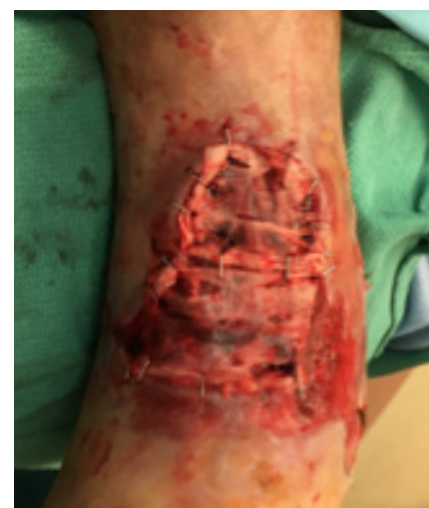

Figure 3: Day 0 two AMNIOCORD allografts placed intraoperatively

Follow-Up

Patient had follow-up visits at the wound care center and showed good wound progression (Figures 5-8). He was taken back to surgery one time after the initial consult for additional debridement. The patient expired prior to the complete closure of the wound.

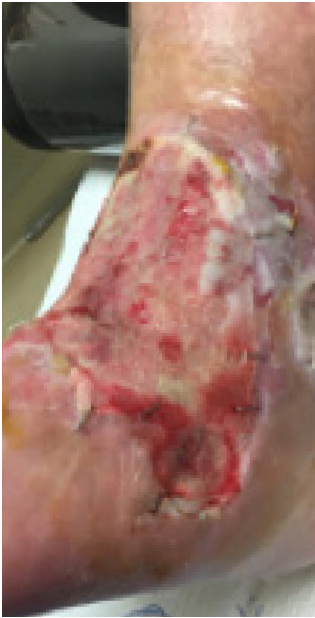

Figure 5: 4 Days postop

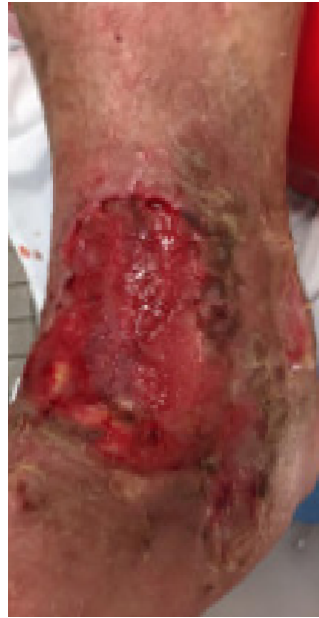

Figure 6: 2 Weeks postop

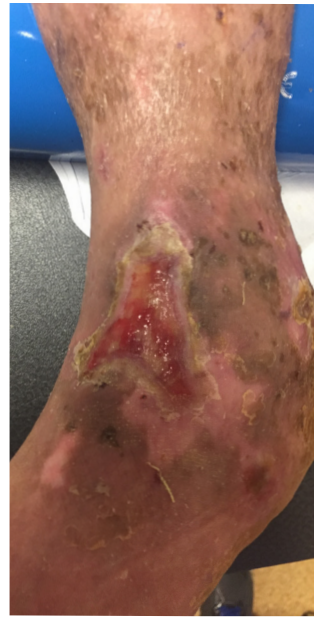

Figure 7: 4 Months postop

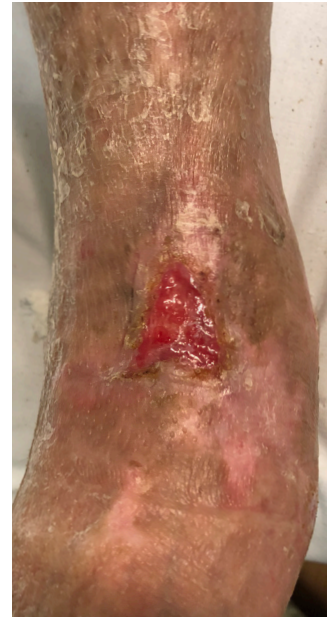

Figure 8: 6 Months postop

Conclusion

AMNIOCORD helped to provide a protective environment to support the healing process. The patient's limb progressed towards closure by secondary intention and avoided an amputation.

Scan code to view
case presentation:



<https://vimeo.com/440382945>

3-Year Chronic Venous Stasis Ulcer With DHACM[†] and NPWT

W. Dotie Jackson, MD | Plastic and Reconstructive Surgery | Jackson, MS

Challenge

Wound closure is achieved through a precise sequence of three phases: inflammation, proliferation, and remodeling. All three phases must occur in the proper sequence and time frame. Chronic wounds do not progress through the healing cascade in a timely manner. While underlying pathology will differ in chronic wounds, some commonalities of these wounds include prolonged or excessive inflammation, persistent infections, formation of drug-resistant microbial biofilms, and the inability of dermal and/or epidermal cells to respond to reparative stimuli. The combination can result in the failure of these wounds to close for prolonged periods with high recurrence rates.³

Clinical History

40-year-old female status post open reduction and internal fixation surgery of an open left ankle fracture, four years prior, presents with a three year history of a non-healing, painful venous stasis ulcer on the LLE, just proximal to the medial malleolus. The patient had received treatment from multiple healthcare providers and wound care centers prior to being seen by me. After obtaining her healthcare records, it was noted that she had been treated with local wound care, topical enzymatic ointments, recombinant DNA therapy, surgical debridement, hyperbaric oxygen therapy, and myriad skin substitutes and biologic dressings. Her prior treatments including Santyl[®], Regranex[®], Apligraf[®], Integra[®], OASIS[®], and PriMatrix[®]. She complained of intense pain. She was upset and frustrated, as this open wound had interfered with her personal life, and the weekly visits to healthcare providers interfered with her employment. Her prior workup had included rheumatology, infectious diseases, endocrine and nutrition. Her comorbidities included well controlled hypertension and diabetes mellitus. At the initial consultation, the wound size was approximately 5 cm x 5 cm, with a 0.7 cm leading edge (Figures 1 & 2); it was painful and exudative.

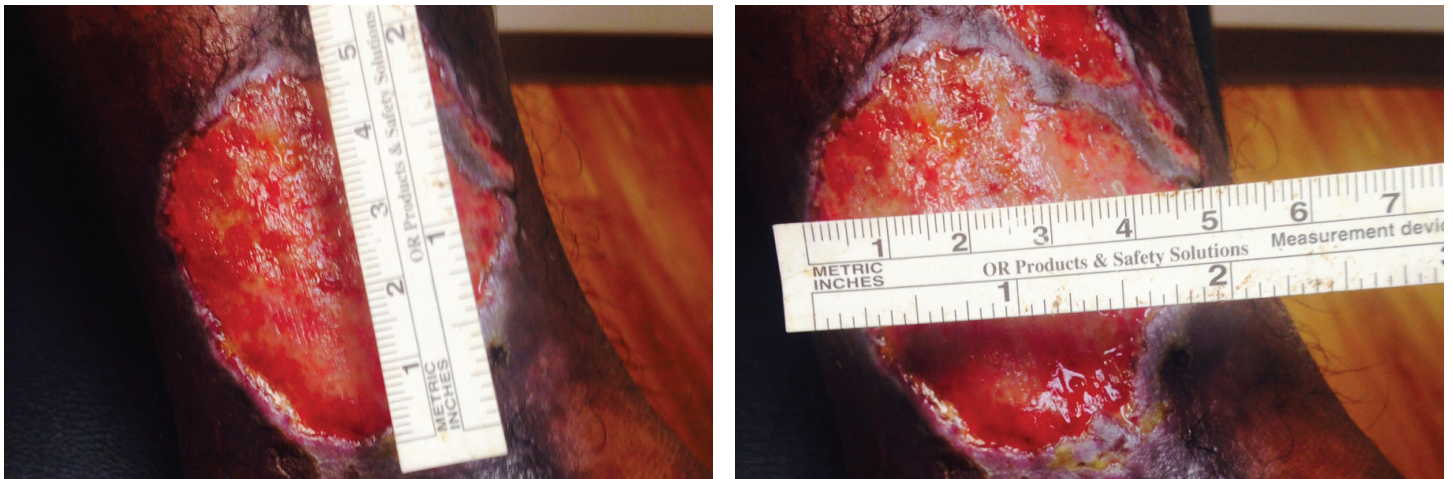

Figure 1 & 2: 5 cm x 5 cm chronic Venous Leg Ulcer (VLU)

[†]This case used EPIXL DHACM which was discontinued on 8/27/21.

Surgical Intervention

Incisional biopsies, wound cultures, and sharp debridement were done in the office. Given this was a chronic wound for over three years, a malignant process had to be ruled out. Negative pressure wound therapy was initiated until the pathology of the biopsy site and cultures of the wound were available; the biopsies and cultures were negative. Radiographs were negative of osteomyelitis. There was no hardware in the zone of the ulcer. The fracture site was well healed.

The wound appeared to have a healthy bed of granulation tissue to support a skin graft. She underwent a STSG with application of NPWT, and was monitored in the hospital for five days. On postop day five, the negative pressure dressing was removed, and the STSG had 100% take. She was discharged to home and seen in the office weekly. Four weeks after the skin graft application, there was epidermal slough, and as the weeks progressed, there was eventually complete loss of the STSG. The donor site healed without event. Local wound care was continued.

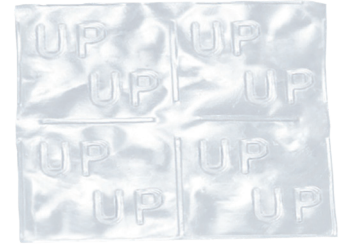

Figure 6: DHACM sheet

She was referred for a vascular workup. She had normal arterial flow, but venous insufficiency was documented. She had venous stents placed and was started on anticoagulation. PriMatrix Dermal Repair Scaffold was used for six weeks with no changes in the wound (Figures 3-5), followed by OASIS Wound Matrix for an additional eight weeks with no significant change in the status of the wound. Her body rejected 80 percent of the skin substitutes, as evidenced by not incorporating the products. A quantitative wound assay was done and found to be normal. There was not an increased amount of zinc metalloproteases found.

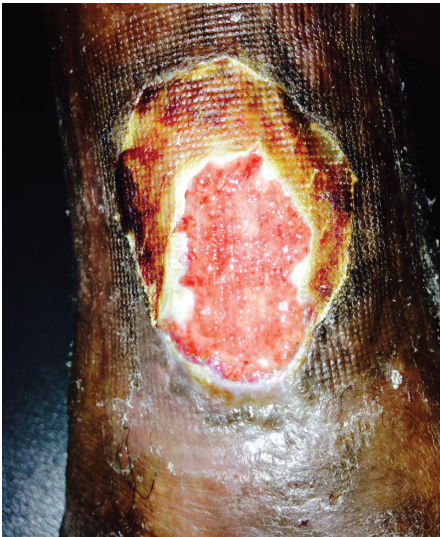

Figure 3: Failed PriMatrix

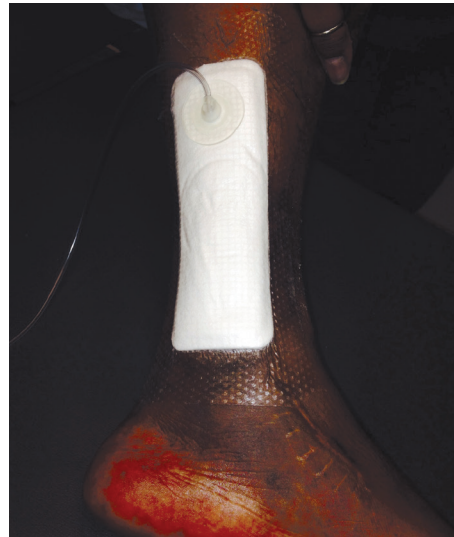

Figure 4: Debridement and NPWT

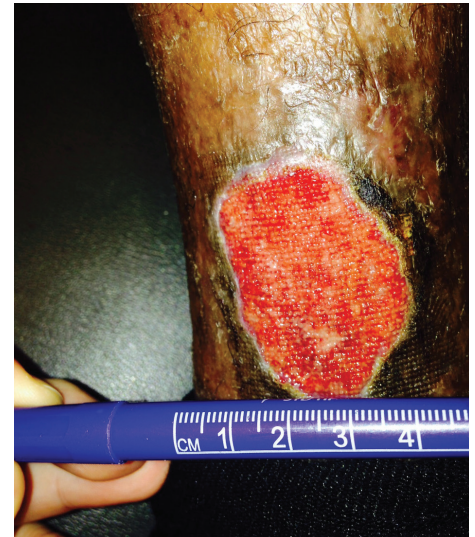

Figure 5: Removal of NPWT one week later

STSG = Split Thickness Skin Graft

A second STSG was performed four months after the venous workup was completed, and the outflow was deemed suitable. The STSG and NPWT dressing was performed, and she remained as an inpatient for five days. Again, the graft was 100% viable at that time and remained so for eight weeks. The graft became unstable again and was lost. The wound was debrided in the office, and a DHACM (Dehydrated Human Amnion/Chorion Membrane) 4 cm x 4 cm graft (Figure 6) was placed onto the wound bed and covered with an NPWT dressing. DHACM provides a protective barrier that supports the healing cascade and protects the wound bed to aid in the development of granulation tissue in acute and chronic closures. The product is a biocompatible human extracellular matrix and contains 300+ regulatory proteins.^{1,4,5}

Within one week, the patient stated her pain had resolved. There was visible ulcer contraction and skin ingrowth noted at the periphery of the wound. An additional DHACM graft was placed two weeks after the initial application, and by Day 35, the ulcer was closed and stable for the first time in more than four years (Figures 7-11). The skin was normal and pliable. The patient was pain free and ready to return to work.

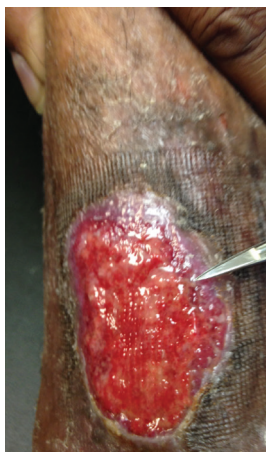

Figure 7: 7 days S/P DHACM + NPWT

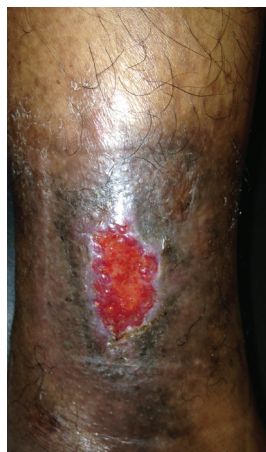

Figure 8: Day 14

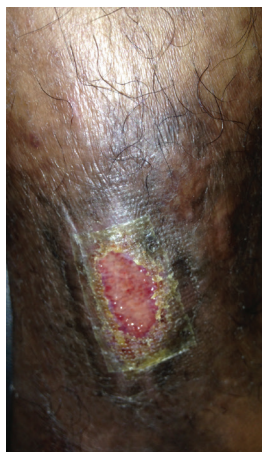

Figure 9: DHACM Application on Day 14

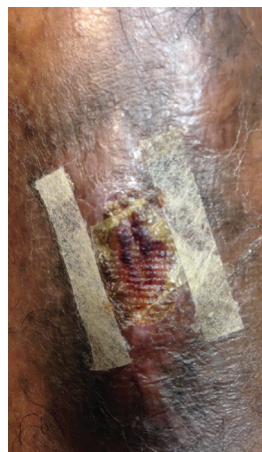

Figure 10: Day 25

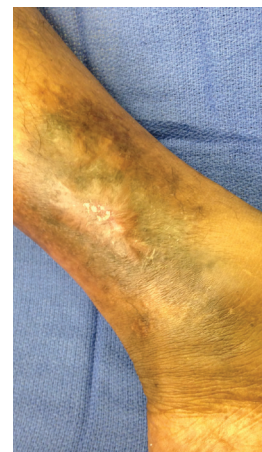


Figure 11: Day 35

Follow-Up

The patient has been seen at three, six, and twelve months. The skin is soft and pliable, and the patient is without complaints. After her journey, she asked me, "Where were you four years ago?"

Conclusion

Patients with multiple comorbidities and venous insufficiency can have significant healing challenges. In this case example, the patient failed multiple treatments using both conventional and advanced wound therapies and STSGs over a three year period. Closure was observed approximately one month after DHACM and NPWT applications were initiated.

S/P = status post

BKA to AKA After Recurrent Dehiscence

Ginger K. Bryant, MD | Orthopaedic Traumatologist and Reconstructive Surgeon | The Orthopaedic Center
Huntsville, AL

Challenge

Chronic wounds, with or without concomitant infection, have been and will continue to be a significant problem in our complex patient population. Nicotine use, peripheral neuropathy, controlled and uncontrolled diabetes, and peripheral vascular disease are only a few of the risk factors that lead to the often unsuccessful eradication of infection and the persistent presence or recurrence of wounds. Whether failure of treatment comes from patient non-compliance or the natural evolution of their medical diagnoses, surgeons continue to look for new knowledge and technology to improve outcomes in these complex situations.

Clinical History

This patient is a 74-year-old male with a complex medical history including chronic obstructive pulmonary disease, obesity, peripheral vascular disease, peripheral neuropathy, and hypertension. He also has an 80 pack year smoking history and is currently smoking two packs of cigarettes per day. He had a below knee amputation one year prior to presentation secondary to chronic osteomyelitis and non-healing wounds on his foot. His surgical site underwent secondary closure twice (Figure 2) and had been dehisced for approximately six months (Figure 3) at his initial visit. The extent of the wound was the complete surgical incision and the distal two inches of tibia was exposed circumferentially.

Surgical Intervention

The patient was taken to the operating room for conversion of his below knee amputation to an above knee amputation. Smoking cessation and follow-up compliance was discussed extensively pre-operatively. The above knee amputation incision dehisced within three weeks of surgery. The patient continued to smoke two packs of cigarettes per day. He underwent two more surgical debridements with secondary wound closures. The surgical plan for the fourth above-knee procedure (Figure 4) included extensive debridement, deep tissue cultures, use of AMNIOFIX (Figure 1) and a layered wound closure.

AMNIOFIX is a dehydrated human amnion/chorion membrane allograft. AMNIOFIX sheets provide a protective barrier that supports the healing cascade and protects the wound bed to aid in the development of granulation tissue in acute and chronic closures. AMNIOFIX provides a biocompatible human extracellular matrix and contains 300+ regulatory proteins.^{1,4,5}

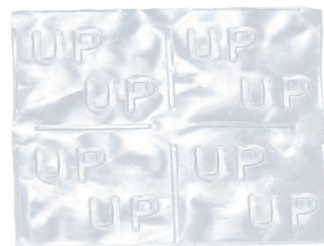

Figure 1: AMNIOFIX sheet

After sharp debridement and extensive irrigation, a 6 cm x 6 cm AMNIOFIX sheet was placed superficial to the muscle layer that had been repaired by myodesis. The subcutaneous layer was reapproximated with non-absorbable suture and the skin closed with nylon suture.

Follow-Up

The patient continued to take the same antibiotics for three weeks and also continued physical therapy. Smoking cessation education was emphasized, again, unsuccessfully. The nylon sutures were removed on postop day 16. A 2 mm sinus presented within the lateral aspect of the incision. This was treated with ¼ inch packing changed twice daily and closed successfully via secondary intent within two weeks (Figure 5).

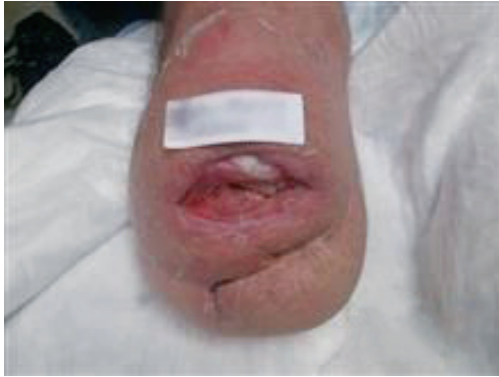

Figure 2: Below knee amputation postoperative wound dehiscence on surgical day of debridement and repeat primary closure

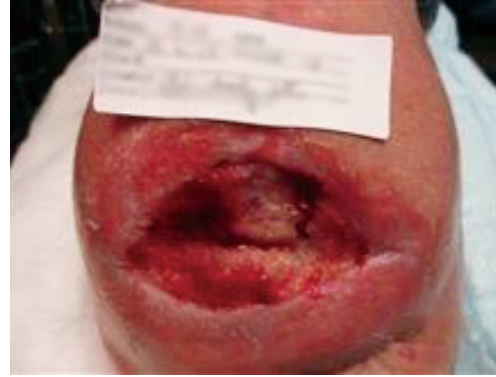

Figure 3: Wound dehiscence less than a month after surgical debridement and primary closure

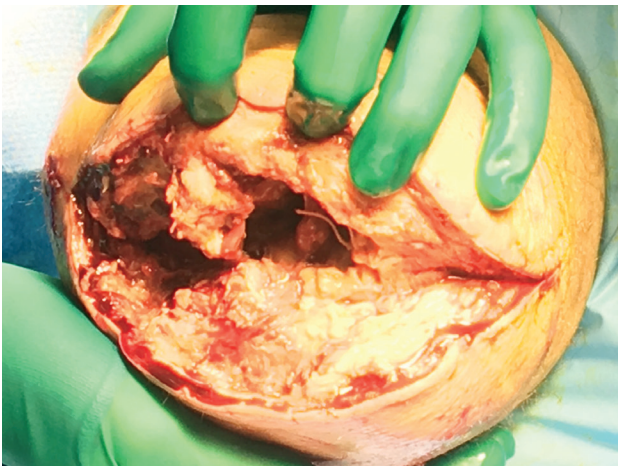


Figure 4: Extensive debridement of recurrent dehiscence of above knee amputation prior to placement of AMNIOFIX

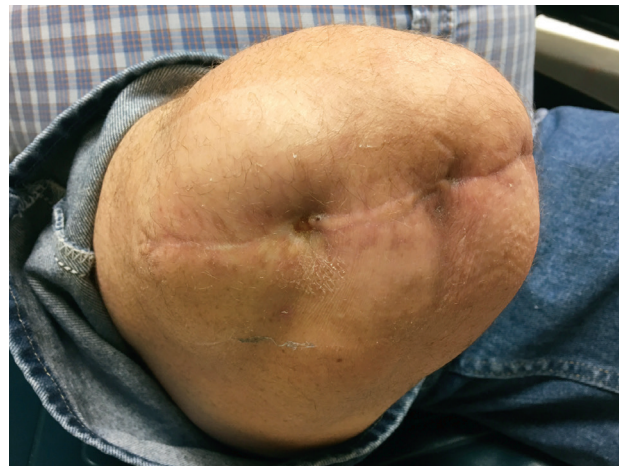

Figure 5: Complete wound closure one month S/P debridement and one AMNIOFIX application

The patient began prosthetic fitting and ambulated on his above knee prostheses, his first prosthetic-assisted ambulation since his initial below knee amputation 18 months prior.



LEARN MORE

CONTACT US: Scan
the code or visit
mimedx.com/contact/

To find out more about MIMEDX® products:

 Please Call: 866.477.4219  Email: customerservice@mimedx.com

REFERENCES: **1.** MIMEDX Internal Report. MM-RD-00086, Proteome Characterization of PURION Processed Dehydrated Human Amnion Chorion Membrane (DHACM) and PURION PLUS Processed Dehydrated Human Umbilical Cord (dHUC) Allografts. **2.** Bullard JD, Lei J, Lim JJ, Masee M, Fallon AM, Koob TJ. Evaluation of dehydrated human umbilical cord biological properties for wound care and soft tissue healing. *J Biomed Mater Res B Appl Biomater.* 2019;107(4):1035-1046. **3.** Frykberg RG, Banks J. Challenges in the Treatment of Chronic Wounds. *Adv Wound Care (New Rochelle).* 2015;4(9):560-582. **4.** Koob TJ, Lim JJ, Masee M, Zabek N, Denozière G. Properties of dehydrated human amnion/chorion composite grafts: Implications for wound repair and soft tissue regeneration. *J Biomed Mater Res B Appl Biomater.* 2014;102(6):1353-1362. **5.** Lei J, Priddy LB, Lim JJ, Masee M, Koob TJ. Identification of Extracellular Matrix Components and Biological Factors in Micronized Dehydrated Human Amnion/Chorion Membrane. *Adv Wound Care (New Rochelle).* 2017;6(2):43-53.